

Hepatoprotective Activities of Leaf Extract of Piper Betle Linn. on CCL₄ Induced Hepatotoxic Male Albino Rats

Punitha S¹, Manivannan S², Karthika C³, Bharathi P⁴

¹Department of Zoology, Kandaswamy Kandar's College of Arts and Science, Velur, Namakkal

²Department of Zoology, Kongunadu Arts and Science College (Autonomous), Coimbatore

³PG and Research Dept. of Biotechnology, Bharath College of Science and Management, Thanjavur

⁴ Corresponding Author

Abstract - The *Piper betle* is one of the antioxidant rich plant. Antioxidants protect degenerative diseases like cancer, carcinogenesis, protein damages, and chronic diseases and reduced cardiac diseases. CCL₄ induce the severe hepatic damages in the liver. The purpose of this study was to investigate the hepatoprotective activity of *Piper betle* leaf extract against the CCL₄ induced hepatotoxic male albino rats. Live male wistar albino rats (150 to 200 gms) were divided into four groups (Group I- normal control, II- CCL₄ treated, III- CCL₄+ leaf extracts treated and IV- CCL₄+Silymarin treated), each group had 5 animals for using the experimental period of 28 days of experiment. Silymarin was used as a positive control. At the end of the experimental period, the rats from each group subjected to diethyl ether anesthesia and blood samples were collected and serum was separated. Serum samples were used to estimate the bilirubin, protein and cholesterol and enzyme assays like AST, ALT and ALP. The liver was excised from each group for the estimation of liver glycogen and histopathological studies. Considerably reduced the impairments of CCL₄ induced (0.1ml/kg/day for 14 days) liver damages in administration with *Piper betle* leaf extract (400mg/kg/day orally for 28 days) treated rats. The histopathological study was showing the normal hepatic cords and absence of necrosis, lesser fatty infiltration. Further we like to infer that *Piper betle* may have the antioxidant properties and inhibited lipid peroxidation in CCL₄ induced hepatic damages.

Index Terms - Piper betle, Carbon tetrachloride, Silymarin, hepatoprotective, fatty infiltration

I.INTRODUCTION

Liver is a large and vital organ in human body. It plays an important role in metabolism, detoxifies chemicals and metabolizes drugs and other functions and regulating homeostasis in the body [10]. Various toxic

agents like chemicals, alcohol, and viruses are initiated to liver injuries of zonal necrosis, chronic hepatitis, cholestasis, fatty liver, tumor, cirrhosis, etc. [26]. CCL₄ is one of the most commonly used hepatotoxins in the experimental study. It is induced severe hepatic damage in liver [11], [15], [34]. Waterfield et al., (1991) [32] reported that, a single dose of CCL₄ induced biochemical and histological damages in the liver cells. CCL₄ induced liver necrosis, cirrhosis, lipid peroxidation of membranes, free radicals, and nitrogen free radicals [1], [13]. Free radicals are highly reactive and interact with cellular macromolecules such as lipids, proteins and DNA leading to a cascade of oxidation and reduction reactions, causing liver damage [13]. Free radicals can be produced accidentally as product of metabolism, by 'leakage' of electrons from electron transport chain and by the formation of superoxide. Deliberate generation of the free radicals occurs during the phagocytosis [5]. Cheeseman et al., (1985) [8] defined the xenobiotics such as CCL₄ has been enhanced the production of free radicals. Free radicals are highly reacting with toxic agents. When the liver is highly toxicated the marker enzymes like alkaline phosphatase (ALP), aspartate transaminase (AST) and alanine transaminase (ALT) are highly leak out from liver into blood stream [2]. Nowadays we used numerous medicines from plants and plant extracts for healthcare. Each and every plant is used for medication in humans and animals [29]. Commonly plants have number of natural antioxidants. Antioxidants protect degenerative diseases like cancer, carcinogenesis, protein damages, and chronic diseases and reduced cardiac diseases. Indeed betle leaves are important part of the Indian traditions and warmly connected with cultural life of Indians especially Tamil peoples and also they are

used betel leaves on very long times in household remedy for digestion, cold, fever, hepatic diseases etc., because Piper betle (betle leaves) is antioxidant rich plant [18], [25]. The purpose of this study was to investigate the hepatoprotective activity of Piper betle leaf extract against CCl₄-induced hepatotoxic male albino rats.

II. MATERIALS AND METHOD

A. Plant extraction

The fresh leaves of Piper betle were collected from agricultural farms in Velur, Namakkal District, Tamil Nadu, India. The leaves were dried under shade and then powdered with a mechanical grinder to obtain fine powder and stored in airtight container. About 500 gm powdered material was subjected to soxhalation and exhausted with 90% Ethanol for 48 hrs. The solvents were evaporated in a rotavapor at 80°C under reduced pressure. The semisolid material obtained was successively extracted in Petroleum Ether (60°-80°C) and Acetone (60°-80°C) by using soxhalat extractor. The extracts were concentrated in a rotary evaporator under reduced pressure. Finally, a reddish – brown coloured (10.17 gms) semi solid material was obtained. It was stored in a refrigerator.



Fig.1. Fresh Piper betle plant



Fig.2. Fresh Piper betle leaf extract

B. Experimental Animals

In the present investigation lives male wistar albino rats weighing 150 to 200 gms were procured from Perundurai medical college, Perundurai. They were housed in well ventilated polypropylene cages at normal room temperature. They were fed with laboratory pelleted feed (marketed by M/s. Hindustan Lever Ltd., Bangalore, India) and clean drinking water ad libitum. Rats were acclimated laboratory condition for period of one week prior to the experiment. All procedures described were reviewed and approved, number: SAC/ IAEC/BC/2017/Ph.D.-002. Dated 11.05.2019.

C. Reference Hepatoprotective Drugs

The present investigation of Piper betle leaf extract was compared with those of a minimal dose (50 mg / kg) of Silymarin a hepatoprotective drug available in the market (reference hepatoprotective drug Silymarin tablets, Micro labs Ltd, Goa, India).

D. Experimental design

After a week, the animals were divided into four groups (Group I, II, III and IV), each group had 5 animals and noted animal's initial weight.

Group I: Served as untreated control. They received the vehicle (Liquid paraffin 0.2ml/kg/day through i.p. route) for 14 days and also received the vehicle (water - 1 ml/animal/day) orally (by using intragastric catheter - IGC) for 28 days.

Group II: CCL₄ induced hepatotoxic control. They were given i.p. injection of CCL₄ (0.1ml/kg/day) in a suspension of liquid paraffin (0.2ml/kg/day through i.p. route) for 14 days and they were given vehicle (distilled water - 1 ml/animal/day) orally (by using intragastric catheter - IGC) for 28 days.

Group III: CCL₄ induced hepatotoxic rats treated with leaf extract of Piper betle. They received i.p. injection of CCL₄ (0.1ml/kg/day) in a suspension of liquid paraffin (0.2ml/kg/day through i.p. route) for 14 days and were simultaneously treated with leaf extract of Piper betle (400mg/kg/day) suspended in the distilled water orally (1 ml/animal/day) orally (by using intragastric catheter - IGC) for 28 days.

Group IV: CCL₄ induced hepatotoxic rats treated with reference standard hepatoprotective drug Silymarin. They received i.p. injection of CCL₄ (0.1ml/kg/day) in a suspension of liquid paraffin (0.2ml/kg/day through i.p. route) for 14 days and were

simultaneously treated with standard drug Silymarin (50mg/kg/day) suspended in the distilled water orally (1 ml/animal/day) orally (by using intragastric catheter - IGC) for 28 days.

All the groups are maintained for 28 days with food and water *Ad libitum* throughout the study period. Water intake, food intake, changes in body weight and mortality were observed during the study period.

E. Collection of sample and biochemical estimation

At the end of the experimental period, the rats from each group subjected to diethyl ether anesthesia and blood samples were collected (cardiac puncture using sterile disposable syringes) and serum was separated by centrifuged 2500 rpm. Serum samples were used to estimation of bilirubin, protein and cholesterol and enzyme assays like AST, ALT and ALP. The liver was excised and washed with normal saline and 10% tissue homogenate was prepared in ice cold 0.1M Tris HCL buffer for estimation of liver glycogen.

The enzyme assays like Aspartate Transaminase (ASP) and Alanine Transaminase (ALT) following by the procedure of Reitman and Frankel (1957)^[24] and Alkaline Phosphatase (ALP) was assayed by the method of King (1965A)^[14].

Biochemical estimations like serum bilirubin was estimated by Malloy and Evelyn (1937)^[17] method, serum protein was determined by following the procedure of Lowry et al., (1951)^[16], cholesterol was estimated by the method of Zak (1977)^[33] and the liver glycogen was estimated by the procedure of Raghuramulu et al., (1983)^[22].

F. Histopathology

The liver was excised from each group and washed with normal saline, fixed with 10% buffered neutral formalin for 48 hrs, then with Bouin's fluide for 6 hrs. They were processed for paraffin embedding. The section were taken at 5 μ m thickness using microtome, processed Alcohol- xylene series and were stained with Alumhaematoxylin and Eosin. The sections were examined microscopically for the evaluation of histopathological changes.

G. Statistical Analysis

The data were analyzed statistically using students't' test and expressed as mean \pm standard error mean (S.E.M.).

After 28 days of treatment, the body weight from each group animals were measured. There was increase in body weight up to 7.56% in Gr. I, 2.8% in Gr. III (CCL₄ + leaf extract treated) and 5.6% in Gr. IV (CCL₄ + Silymarin treated) and significantly decrease in body weight up to 4.21% Gr. II (CCL₄ treated) compared to day one. The food consumption and water intake also normally recorded in the Gr. I, III, IV and significantly decreased in Gr. II - CCL₄ induced hepatotoxic rats (Table 1).

The elevated level of serum enzymes of AST, ALT and ALP was recorded in Gr. II - CCL₄ induced hepatotoxic rats compared with control group. Gr. III and Gr. IV was significantly decreased the enzyme levels compared with Gr. II - CCL₄ induced hepatotoxic rats. The level of bilirubin was substantially increased CCL₄ induced group (2.348mg/dl) compared with normal group (0.557mg/dl) and decreased the bilirubin level in plant extract treated group and Silymarin treated group compared with Gr. II (CCL₄ induced group). The serum protein level was significantly decreased to 5.419 mg/dl in CCL₄ induced rats from 8.74 mg/dl in control group. The leaf extract treated group was almost normal compared with the standard drug Silymarin treated group. The level of cholesterol was vastly increased (108.57 gm/dl normal level was 68.52 gm/dl). The leaf extract treated group III was 77.181mg/dl and Silymarin treated (group IV) 71.501mg/dl was recorded. The liver glycogen was considerably decreased in group II and other groups were almost normal compared with control group (Table 2).

On histological study, normal histological architecture and clear cytoplasm with prominent nucleus was observed in control group. In group II CCL₄ toxicated animals, severe hepatotoxicity on degenerative lesion, vacuolation, sinusoidal dilation, periportal fibrosis, fatty degeneration in hepatocytes, focal necrosis, infiltration of lymphocytes and kupffer cell proliferation were observed. The liver section of leaf extract treated group III and Silymarin treated group IV animals shown nearly normal architecture compared with CCL₄ toxicated group animals.

Table: 1. General parameters in various experimental group animals

III. RESULT

Experimental Groups	Body weight (g)		Water intake (ml/rat/day)	Food consumption (g/rat/day)
	Initial	Final		
Group I - Normal control	155±3.5	182±2.5*	29±2.0	35±3
Group II- CCL ₄ induced	160±3.5	145±3.5*	23±2.5 ^a	27±3 ^a
Group III - CCL ₄ + leaf extract treated	164±3.5	174±2.5*	28±1.5 ^b	32±3 ^b
Group IV - CCL ₄ + Silymarin treated	160±2.0	180±2.5*	29±2.0 ^c	34±2 ^c

Each value mean ± SEM (no=5). *: p<0.05 compared within the same group. a : Group II Vs Group I. b : p<0.05 Group III Vs Group II. c : p<0.05 Group IV Vs Group II

Table: 2. Effect of various experimental groups on some serum chemical parameters and liver glycogen

Experimental Groups	Parameters						
	AST (IU/L)	ALT (IU/L)	ALP (IU/L)	Bilirubin (mg/dl)	Protein (mg/dl)	Cholesterol (mg/dl)	Liver Glycogen (mg/g)
Group I - Normal control	58.68±1.34	48.36±2.6	33.42±3.25	0.557±0.12	8.74±0.23	68.52±3.32	23.54±1.75
Group II CCL ₄ induced	174.56±5.34 ^a	97.80±2.36 ^a	110.5±8.7 ^a	2.348±0.35 ^a	5.419±0.198 ^a	162.39±3.85 ^a	18.22±1.51 ^a
Group III - CCL ₄ + leaf extract treated	102.42±3.27 ^b	58.83±1.08 ^b	42.64±2.57 ^b	1.098±0.17 ^b	7.490±0.310 ^b	123.95±3.8 ^b	22.31±1.75 ^b
Group IV - CCL ₄ + Silymarin treated	71.02±1.73 ^c	52.24±1.64 ^c	41.30±2.71 ^c	0.634±0.42 ^c	8.228±0.272 ^c	117.96±4.42 ^c	23.09±1.6 ^c

Each value mean ± SEM (no=5). a : p<0.05 Group II Vs Group I. b : p<0.05 Group III Vs Group II. c : p<0.05 Group IV Vs Group II

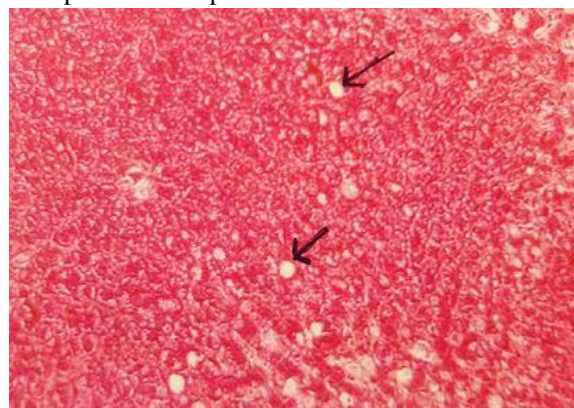


Fig.3. Liver section of group I control rat showing normal architecture (H&E 100x).

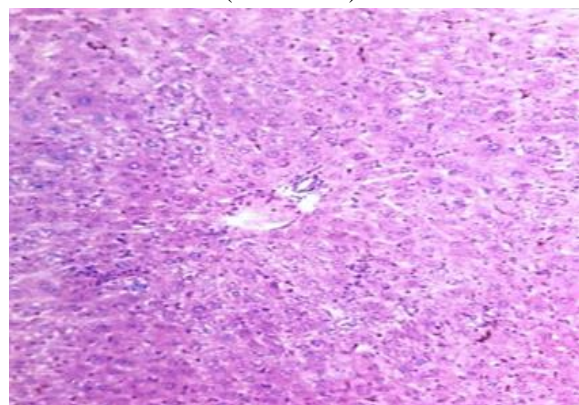


Fig.4. Liver section of CCl₄ induced hepatotoxic group II rat showing vacuolated hepatocytes (arrow) (H&E 100x).

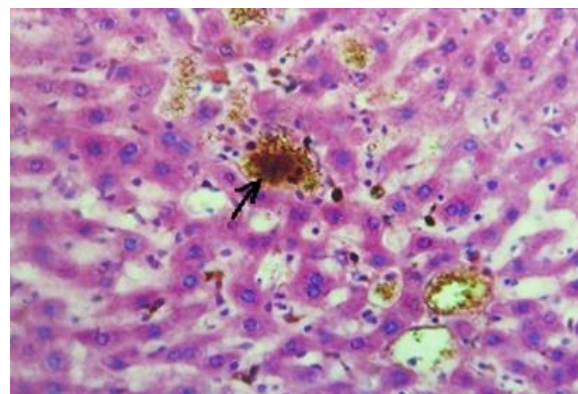


Fig.5. Liver section of CCl₄ induced hepatotoxic group II rat showing presence of hemosiderin pigments in heavy sinusoidal distension (H&E 250x).

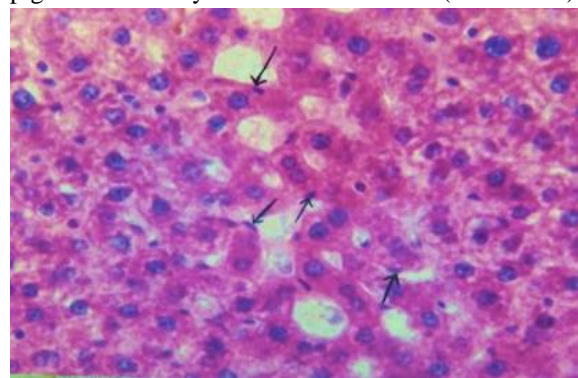


Fig.6. Arrow indicates presence of kupffer cells in sinusoidal lining of CCl₄ induced hepatotoxic rat (H&E 400x).

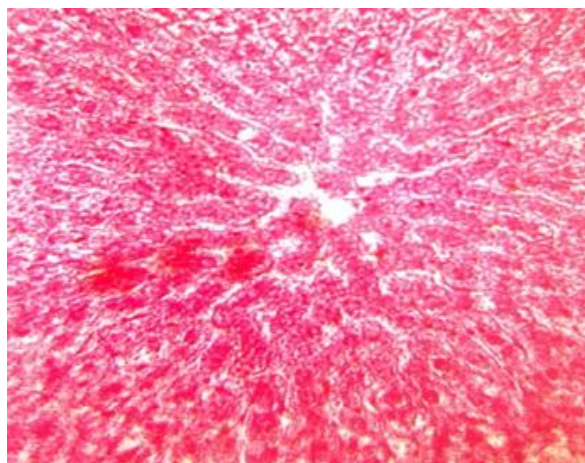


Fig.7. Liver section from CCl₄ + leaf extract treated group III rats shows normal hepatic cords with less sinusoidal distension (H&E 200x).

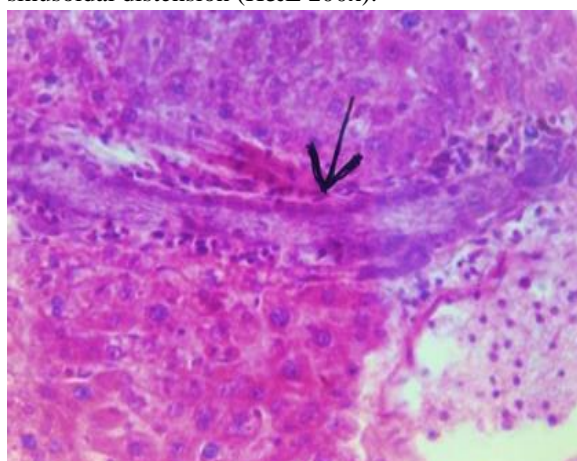


Fig.8. Liver section showing mild hyperplasia of biliary epithelium (arrow) in CCl₄ + leaf extract treated group III (H&E 250x).

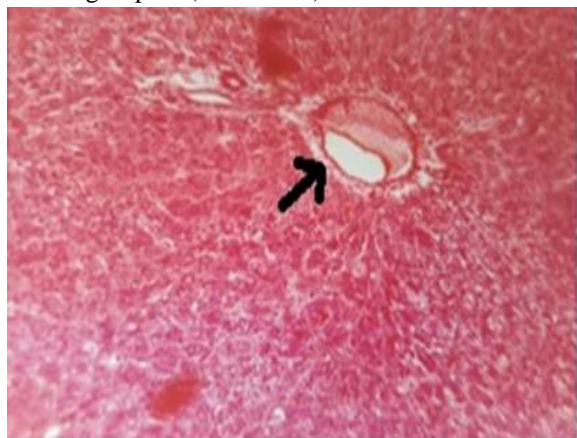


Fig.9. Liver section of CCl₄ + Silymarin treated group IV rats showing normal central vein (arrow) and less fatty infiltrations (H&E 100x).

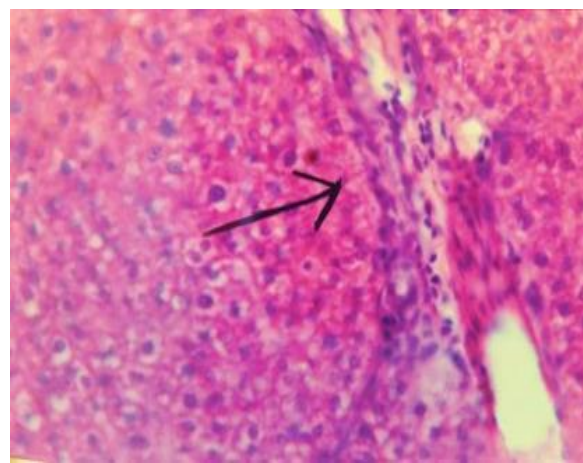


Fig.10. Presence of mild sinusoidal space (arrow) in CCl₄ + Silymarin treated group IV rat (H&E 200x).

IV. DISCUSSION

Present study was proved that the protective ability of leaf extracts of Piper betle on CCl₄ induced hepatic damaged rats. We observed a significant loss of body weight about 15 gm and recorded considerably elevation marker enzymes of AST, ALT and ALP and other biochemical parameters like serum bilirubin, cholesterol except the level of serum protein and liver glycogen in CCl₄ induced hepatotoxic group II animals when compared with control group (Table 2). These biochemical parameters in group II animals was conform the toxic response and metabolic dysfunction of liver. The same findings of Venukumar and Latha (2004)^[30] who reported that the decline body weight and marker enzymes were suggestively increased in CCl₄ treated animals during their study period. CCl₄ induced hepatotoxicity in liver and triggers the generation of toxic radicals [23]. CCl₄ metabolized by cytochrome P-450 initiates the cellular oxidants and lipid peroxidation in cellular membranes and leading to necrosis [4]. When, enhanced lipid peroxidation persuaded tissue destruction and failure of antioxidant defense mechanisms to prevent formation of excessive free radicals. These free radicals induced oxidative stress [9]. As a result, CCl₄ toxicated animals couldn't take food, loss of body weight and sever hepatic damage. Hepatic damage caused after CCl₄ treatment the liver marker enzymes like AST, ALT and ALP presented higher concentration in liver cytoplasm [12], because these enzymes made liver function. [27]. In group III hepatotoxic with leaf extract treated animals much significantly gain in the body weight

and the level of marker enzymes, serum bilirubin, cholesterol, serum protein and liver glycogen nearly normalized when compared with toxicated group II animals. Our study material of Piper betle leaf extracts have such antioxidant properties in protecting the hepatic damages. Padma et al., (1989)^[21] reported that certain medicinal properties accredited to Piper betle which include antioxidant, hepatoprotective, cardiovascular etc. Generally, most of the phytochemical studies shown, that plants contain alkaloids, flavonoids, tannins and saponins. Alkaloids and flavonoids used for antiviral, antibacterial and anticancer agent [6], [31], [3]. The Piper betle leaf extracts playing a pivotal defensive role against oxidative stress and also showed free-radical scavenging activity [20]. Our findings authenticated the leaf extract of Piper betle protect the liver against CCl₄ toxicity.

On histological examinations, we observed degenerative lesion, vacuolation, sinusoidal dilation, periportal fibrosis, fatty degeneration in hepatocytes, focal necrosis, infiltration of lymphocytes and kupffer cell proliferation in CCl₄ treated animals [3], [19], [31]. When the liver stressed more kupffer cells present in the cytoplasm. Kupffer cells are active in fat metabolism and in the formation bile pigments. [28]. In our study we observed proliferation the level of serum cholesterol in CCl₄ treated group animal. In leaf extracts of Piper betle treated group were almost normal compared with the standard drug Silymarin treated group and control group animals. This histological examination was confirmed our study material produce their protective action against CCl₄ induced hepatotoxicity.

V. CONCLUSION

Our study justifies that the leaf extract of Piper betle play against CCl₄ induced impairments and preventing the liver disorders. The mechanism by which the hepatoprotective activity and antioxidant properties were achieved by drug needs to be further investigated. Estimation of antioxidant enzymes and biochemical parameters may give more insight into mechanisms and action of the leaf extract of Piper betle. Further study with the purified active principle from the leaf extract of Piper betle may enlighten its role as hepatoprotective agent.

REFERENCES

- [1] Adewale OB, Adekeye AO, Akintayo CO, Onikanni A and Sabiu Saheed. 2014. Carbon tetrachloride (CCl₄)-induced hepatic damage in experimental Sprague Dawley rats: Antioxidant potential of *Xylopiia aethiopicia*. *The Journal of Phytopharmacology*. 3(2): 118-123.
- [2] Akram Eidi, Pejman Mortazavi, Maryam Bazargan, Jalal Zaringhalam. 2012. Hepatoprotective activity of cinnamon ethanolic extract against CCL4-induced liver injury in rats. *EXCLI Journal*. 11: 495-507.
- [3] Asif Mir, Farida Anjum, Naveeda Riaz, Hina Iqbal, Hussain Mustatab Wahedi, Jabar Zaman Khan Khattak, Muhammad Asrar Khan and Malik SA. 2010. Carbon Tetrachloride (CCl₄) - induced hepatotoxicity in rats: Curative role of *Solanum nigrum*. *Journal of Medicinal Plants Research*. 4(23): 2525-2532. <http://www.academicjournals.org/JMPR>
- [4] Atta ur Rehman, Ayisha Waheed, Rabia Tariq, Muhammad Zaman and Muhammad Javaid Tahir. 2018. Anti-fibrotic effects of *polygonum plebeium* r.br. in CCl₄- induced hepatic damage and fibrosis in rats. *Biomedical Research and Therapy*. 5(4): 2223-2233.
- [5] Babior BM. 1978. Oxygen dependent microbial killing by phagocytes. *New England journal of medicine*. 298(12): 659-668.
- [6] Babu BH, Shylesh, BS and Padikkala J. 2001. Antioxidant and hepatoprotective effect of *Acanthus ilicifolius*. *Fitatherapia*. 72: 272- 277.
- [7] Carl A Burtis and Edward R. Ashwood Tietz. 1999. *Textbook of Clinical Chemistry*. 3rd edition. 1133-1168.
- [8] Cheeseman KH, Albano E, Tomasi A and Stater TF. 1985. Biochemical studies on the metabolic activation of haloalkanes. *Environmental health perspective*. 64: 84-101.
- [9] Dahiru D, Mamman DN and Wakawa HY. 2010. *Ziziphus mauritiana* fruit extract inhibits carbon tetrachloride-induced hepatotoxicity in male rats. *Pakistan Journal of Nutrition*. 9: 990-993.
- [10] Deepak K Dash, Veerendra C Yeligar, Siva S Nayak, Tirtha Ghosh, Rajalingam D, Pinaki Sengupta, Bhim C Maiti, Tapan K Maity. 2007. Evaluation of hepatoprotective and antioxidant activity of *Ichnocarpus frutescens* (Linn.) R.Br.

- on paracetamol-induced hepatotoxicity in rats. *Tropical Journal of Pharmaceutical Research*. 6(3): 755-765.
- [11] Dineshkumar G, Rajakumar R, Mani P and Johnbastin TMM. 2013. Hepatoprotective activity of leaves extract of *Eichhornia crassipes* against CCL4 induced hepatotoxicity albino rats. *International Journal of Pure and Applied Zoology*. 1(3): 209-212.
- [12] El-Sayed YS, Lebda MA, Hassinin M, Neoman SA. 2015. Chicory (*Cichorium intybus* L.) root extract regulates the oxidative status and antioxidant gene transcripts in CCl4-induced hepatotoxicity. *PLoS One*. 10: e0121549.
- [13] Irshad M and Chaudhuri S. 2002. Oxidant antioxidant system. Role and significance in human body. *Indian Journal of Experimental Biology*. 20: 1233-1239.
- [14] King J. 1965. The hydrolases – acid and alkaline phosphatases. In *practical clinical enzymology* (Ed. Van. D). Norstand Company Limited. 191-193.
- [15] Korsrud GO, Grice HC and McLaughlin JM. 1972. Sensitivity of several serum enzymes in detecting carbon tetra chloride induced liver damage in rats. *Toxicology of Applied Pharmacology*. 22: 474-483.
- [16] Lowry OH, Rosenbrough, HJ, Farr AL and Randall RJ. 1951. Protein measurement with the Folin - phenol reagent. *Journal of Biological Chemistry*. 193: 265-275.
- [17] Malloy HT and Evelyn KA. 1937. The determination of bilirubin with the photoelectric colorimeters. *Journal of Biological Chemistry*. 119: 481-483.
- [18] Manoj Kumar Kar, Sanjeet Kumar and Padan Kumar Jena. 2017. Antioxidant activities of leaf extracts of some common betel varieties (*Piper betle* L.) available in Odisha. *International Journal of Pharmaceutical sciences and Research*. 8(4): 1776-1780.
- [19] Nakamura Y, Torikai K and Ohigashi H. 2001. Toxic dose of a simple phenolic antioxidant, protocatechuic acid, attenuates the glutathione level in ICR mouse liver and kidney. *Journal of Agricultural Food Chemistry*. 3: 5674-8.
- [20] Nikhil Kumar, Pragya Misra, Anuradha Dube, Shailja Bhattacharya, Madhu Dikshit and Shirish Ranade. 2010. *Piper betle* Linn. a maligned Pan-Asiatic plant with an array of pharmacological activities and prospects for drug discovery. *Current Science*. 99(7): 922-932.
- [21] Padma PR, Lalitha VS, Amonkar AJ and Bhide SV. 1989. Anticarcinogenic effect of betel leaf extract against tobacco carcinogens. *Cancer Lett.*, 45: 195–202.
- [22] Raghuramulu N, Nair MK and Kalyanasundaram SA. 1983. *Manual of laboratory techniques*. National institute of nutrition, Hyderabad. 96-98.
- [23] Recknagel RO and Glende EA. 1989. *Handbook of free radicals and antioxidants in biomedicine*. Eds. Journal of Miguel, A.T. Quintarulla, Wober. H.CRC Boca Raton FL. 16C: 3-16.
- [24] Retimen S, Frankel SA. 1957. Colorimetric method for determination of serum glutamic oxaloacetic and glutamic pyruvate transaminases. *American Journal of Clinical Pathology*. 28: 56-63.
- [25] Rintu D, Shinjini M, Kaustab M, Pramathadhip P, Umesh PS and Banerjee ER. 2015. Antioxidant and anti-inflammatory activities of different varieties of *Piper* leaf extracts (*Piper betle* L.) *Journal of Nutrition & Food Sciences*. 5: 5.
- [26] Rojini Athokpam, Meenakshi Bawari, Manabendra Dutta Choudhury. 2017. Hepatoprotective activity of aqueous extract of *Oxalis debilis* kunth against CCL4 - induced liver damage. *Asian Journal of Pharmaceutical and Clinical Research*. 10(9): 231-235.
- [27] Sheila Sherlock and James Dooley. 1993. *Assessment of liver function in diseases of the liver and biliary system*. Oxford Blackwell Scientific Publications, London. 9: 17.
- [28] Somit Dutta, Arnab Kumar Chakraborty, Priyanka Dey, Pallab Kar, Pokhraj Guha, Subhajit Sen, Anoop Kumar, Arnab Sen and Tapas Kumar Chaudhuri. 2018. Amelioration of CCl4 induced liver injury in swiss albino mice by antioxidant rich leaf extract of *Croton bonplandianus* Baill. *PLOS ONE*. <https://doi.org/10.1371/journal.pone.0196411>.
- [29] Srinivasa Rao A, Mohammed Fazil Ahmed and Mohammed Ibrahim. 2012. Hepatoprotective activity of *Melia azedarach* leaf extract against simvastatin induced hepatotoxicity in rats. *Journal of Applied Pharmaceutical Science*. 02 (07): 144-148.

- [30] Venukumar MR and Latha MS. 2004. Effect of *Coscinium fenestratum* on hepatotoxicity in rats. *Indian Journal of Experimental Biology*. 42: 792-797.
- [31] Vinoth Kumar P, Sivaraj A, Elumalai EK and Senthil Kumar B. 2009. Carbon tetrachloride-induced hepatotoxicity in rats - protective role of aqueous leaf extracts of *Coccinia grandis*. *International Journal of PharmTech Research*. 1(4): 1612-1615.
- [32] Waterfield CJ, Turton JA and Scales MDC. 1991. Taurine, a possible urinary markers of liver damage: a study of taurine, excretion in carbon tetra chloride –treated rats. *Archive toxicology*. 65(7): 458-555.
- [33] Zak B. 1977. Cholesterol methodologies. A review of *Clinical Chemistry*. 23: 1201.
- [34] Zhang H, Yu CH, Jiang YP, Peng C, He K, Tang JY, Xin HL. 2012. Protective effects of polydatin from *Polygonum cuspidatum* against carbon tetrachloride-induced liver injury in mice. *PLOS One*.; 7: e46574. <https://doi.org/10.1371/journal.pone.0046574> PMID: 23029551